Middle East Journal of Applied Sciences, 4(3): 539-554, 2014
ISSN 2077-4613

Protective Effect of Some Medicinal Plants and Zinc on Some Serum Parameters and Histopathological Features of Liver, Kidney and Testis in Rats Treated with Cadmium

Abd El- Hamid A.A., Badr M., Helal, A.F. and Zaid A.A.

Animal production Dept. Faculty of Agriculture, Al - Azhar University, Cairo, Egypt.

ABSTRACT

This study was designed to evaluate the protective effect of Nigella sativa, garlic or zinc against cadmium toxicity. A total number of 48 male albino rats were distributed into 8 groups, 6 rats each, to receive the folloing eight treatment groups (1) control, (2) 10 mg cadmium /kg B.W, (3) 10 ml of Nigella sativa extract / kg B.W, (4) 10 ml garlic extract / kg B.W, (5) 2.2 mg zinc / kg B.W, (6) 10 ml Nigella sativa extract / kg B.W plus 10 mg cadmium / kg B.W, (7) 10 ml garlic extract / kg B.W plus 10 mg cadmium / kg . B.W (8) 2.2 mg zinc / kg, B.W plus 10 mg cadmium / kg B.W. Rats were orally administered their respective doses every other day for 60 days. Blood samples were collected at 30 and 60 days from the beginning of treatments. At the end of experiment all rats were sacrificed and target organs (liver, kidneys and testis) were collected for histopathological examination. The achieved results indicated that oral administration of cadmium caused central vein congestion and mild congestion of hepatic sinusoids and showed congestion in interstitial blood vessels with extravasated R.B.Cs in the kidney section. The results also showed that cadmium caused mild congestion of seminiferous blood vessels in testis. Furthermore, the obtained results displayed that treatment with cadmium was significantly decreased serum total protein, albumin and significantly increased the activities of ALT, AST and serum urea. On the other hand, oral administration of Nigella sativa, garlic or zinc in combination with cadmium alleviated the toxic effect of cadmium on liver, testes, serum total protein, albumin and activities of ALT and AST enzymes. Also, the results revealed that treatment with Nigella sativa, garlic or zinc did not show any significant effect against the toxic effect of cadmium on kidney structure and Serum urea.

Key words: *Cadmium, garlic, Histopathological, Kidney, Liver, Nigella sativa, rats, testis, zinc*

Introduction

Cadmium is an environmental contaminant that has been recognized to be a risk factor in humans (El Heni *et al.,* 2009). It is present in air, water, food and cigarette smoke (Friberg *et al.,* 1992). Cadmium is mainly used in the industry for coating steel, glass and plastics (including polyvinyl chloride), and for nickel cadmium battery production (Tsalev and Zaprianov, 1993).

Administration of cadmium caused a significant alteration in hepatic and renal functional markers in serum viz. total protein, albumin, alanine transaminase. Likewise, cadmium administration caused prominent pathological changes in liver were sever vascular and sinusoid congestion with diffuse of degenerative changes and mononuclear infiltration into peripheral areas, while the kidney showed vascular and glomerular congestion, cloudy swelling of tubular epithelium (Lakshmi *et al.,* 2012).

Obianime and Roberts, (2009) reported that cadmium caused positively correlated does - and time - dependent destruction of the histology of the liver, kidney and testes. These were characterized by vascular congestion, vacuolation, destruction of the seminal epithelial layers, focal necrosis of nucleus, oedema of the seminal epithelia layers, focal necrosis of nucleus, oedema of the seminiferous tubules and reduction of spermatogenesis. Cadmium also caused granular and eosinophilic cytoplasm, enlargement of sinusoids with kupffer cells, haemorrhage and apoptosis of cells.

Rajendar *et al.,* (2011) observed that cadmium induced toxicity in testicular tissue which could be attributing to the excessive generation of free radicals and impairment of antioxidant defenses. Impaired testicular tissue function was revealed by significant alteration in testicular functional markers, peroxidation markers, spermatodynamic count and histomorphometry.

Plants are the green factors in our planet, they convert carbon dioxide and water to carbohydrates, and nitrogen to amino acids. Besides food, plants are considered the nature's green pharmacy, which provide drugs to maintain the good health and to restore the failed health of humans. The medical arts had its origin when mankind first began to use remedial measures to get rid of their pains, sufferings and other illnesses. For that reason it can be using medicinal plants to heal by preparing potions from these plants (Badr *et al.,* 2012).

Garlic is a commonly used in food and its medical properties have been well recognized since time immemorial. Garlic is a good source of compounds with a positive impact on human health and those compounds include sulphur- containing compounds and flavonoids. Also, findings have shown that garlic have

Corresponding Author: Abd El- Hamid A.A., Animal production Dept. Faculty of Agriculture, Al – Azhar University, Cairo, Egypt.

good beneficial health effects including antibacterial, anticarcinogenic, anti-inflammatory, hypolipidemic, hypoglycemic, antifungal and anti-atherosclerotic properties and antioxidant activity (Vazquez - Prieto *et al.*, 2011 and Ademiluyi *et al.*, 2013).

Nigella sativa L., commonly known as black seed or black cumin. It is used in folk medicine as a natural remedy for a number of diseases such as asthma, hypertension, diabetes, inflammation, cough, bronchitis, headache, eczema, fever, dizziness and gastrointestinal disturbances. Furthermore, the pharmacological and toxicological studies have demonstrated that crude extract or ethanolic extract of nigella sativa and some of its active constituents might have protective effect against renal ischemia -reperfusion-induced oxidative injury and nephrotoxicity and hepatotoxicity that induced by either disease or chemicals (Ali and Blunden, 2003 and Hosseinzadeh and Montahaei, 2007).

Zinc is well known as essential element and cofactor of antioxidant enzymes such as copper, zinc-superoxidase dismutase (CuZn SOD) which dismutase O_2 to H_2O_2 (first step of the antioxidant pathway) (El - Heni *et al.*, 2009).

The present study was designed to ascertain the effect of medicinal plants (garlic or Nigella sativa) or zinc on cadmium toxicity that induced alteration of some physiological parameters and liver, kidney and testes structure (histopathology) of albino rats.

Materials and Methods

The study was performed at Animal house belonging to Animal Production Department, Faculty of Agriculture, Al-Azhar University, Cairo, Egypt.

Experimental Animals:

The Albino rats used in this study were obtained from Egyptian organization for biological products and vaccines, Cairo, Egypt and raised in the animal house. Animals were housed in cages. The mean ambient temperature ranged from 27 to 31 ^{o}C during the experimental period. The photoperiod was approximately 12 hours light / dark cycle . The standard laboratory chow and tap water were provided *ad libitum*. All animals were healthy and clinically free from any diseases.

Preparation of medicinal plants:

Fresh bulbs of garlic and seeds of Nigella sative were purchased from the local market of Cairo city. About 100g bulbs of garlic and 100g powder of Nigella sativa seeds was added to 100ml of distilled water and crushed in a mixing machine. The resultants were squeezed and filtered through a fine cloth then the filtrates were quickly frozen until used (Suru, 2008).

Experimental design:

The study included 48 adult male albino rats, with an average live body weight of 120g (ranged from 100 - 140g). Rats were acclimatized for 2 weeks before starting the experiment then the rats were divided randomly into 8 equal groups each contained 6 rats. The groups were assigned at random to one of the following treatments.

Group 1: Control group orally administered with 10 ml distilled water/kg B.W.
Group 2: Cadmium dissolved in distilled water and administered at the dose of 10mg / kg B.W.
Group 3: Rats treated with 10 ml of Nigella sativa extract / kg B.W.
Group 4: Rats treated with 10ml of garlic extract / kg B.W.
Group 5: Rats treated with 2.2mg zinc / kg B.W.
Group 6: Rats treated with 10mg cadmium / kg B.W. plus 10ml of Nigella sativa extract / kg B.W.
Group 7: Rats treated with 10mg cadmium / kg B.W. plus 10ml of garlic extract / kg B.W.
Group 8: Rats treated with 10 mg cadmium / kg B.W. plus 2.2 mg zinc / kg B.W.

The selection of sublethal dose of cadmium was according to (Al-Hashem *et al.*, 2009).

Animals were treated orally with the tested compounds every other day for 60 days. The doses of treatments were calculated according to the animal's body weight before treatment. Blood samples were taken from the orbital vein of rats and collected into a heparinized tubes. Blood samples were centrifuged at 3000 rpm for 15 min. to obtain Serum . Serum was removed and kept into Ependorff tubes and stored in a deep freezer (-20°C) until analyzed. At the end of the experiment rats were sacrificed to obtain liver, kidney and testis. Immediately after extraction, the target organs were immersed in formalin 10% for two days, then washed in water, dehydrated in ascending grade of ethyl alcohol and finally cleared by xylene then embedded in melted paraffin wax. The organs block was sectioned at six microns cut and stained by eosin and heamatoxylin according to (Pearse, 1968).

Serum Analyses:

Serum urea concentration was determined by using enzymatic colorimetric method according to (Tobacco *et al.,* (1979). Serum total protein was determined using colorimetric method according to (Henry, 1964). Serum albumin was measured using kits according to method of (Dumas and Biggs, 1972). Serum globulin was calculated by subtraction of albumin from the total protein. Serum AST was determined by using a quantitative colorimetric method according to (Henry, 1974). Serum ALT was determined by using a colorimetric method according to (Reitman and fronkel, 1957).

Statistical Analysis:

Data were subjected to analysis of variance using SAS software program package (1998). Also, significant differences among means were determined by Duncan's multiple range test (Duncan, 1955) at 5% level of significant. Data were analyzed by one way method using the following model. $Y_{ij} = u + N_i + e_{ij}$ Where Y_{ij} = the observed value, u = population means, N_i = the effect of treatment, e_{ij} = the standard error.

Results and Discussion

Histopathological examination:

Liver histopathological changes:

The liver structure of the control, Nigella sativa, garlic and zinc groups showed preserved normal lobular architecture. The central vein and portal tracts were normal. The hepatocytes were normal in arrangement, sinusoid and their cytoplasm and nuclei were normal (Fig. 1, 3, 4 and 5).

In rats group treated with cadmium liver section showed preserved normal lobular architecture but the central vein was congested and mild congested was observed in hepatic sinusoids (Fig. 2). The same findings were noticed previously in rats liver after administrated with cadmium (Masso *et al.,* 2007 and El - Bamby 2010). Masso *et al.,* (2007) found that cadmium acetate at level of 10mg/L caused mycrocitic anemia in the pups as well as oxidative damage in the liver.

On the other hand, addition of Nigella sativa, garlic or zinc with cadmium diminished the harmful effect of cadmium on hepatic sinusoids (Fig. 6, 7, 8). These results are in agreement with those obtained by (Obioha *et al.,* 2009) showed that cadmium induced oxidative damage in rat liver but this effect can be reduced by adding high dose of onion and moderate dose of garlic extracts to the rats. This reduction in oxidative damage in rat liver may be due to the reduce lipid peroxidation and enhanced antioxidant defense system that is insufficient to prevent and protect from cadmium induced hepatotoxicity.

Abd and Al-Baghdadi (2009) reported that the use of garlic oil possess hepatoprotective activity by restoring the normal hepatic functions and potentiating the bio- defense system of the liver against hepatotoxicity produced by CCl_4 administration. El-Heni *et al.,* (2009) established that application of selenium or zinc during exposure to cadmium, only partial corrective effects on cadmium induced oxidative stress in the liver. Kang *et al.,* (2008) suggested that dietary zinc supplementation may have beneficial effects in alcoholic liver disease.

Kidney histopathological changes:

The kidney structure of the control, Nigella sativa, garlic, cadmium and zinc groups showed preserved normal architecture. The cortex showed normal renal glomeruli and tubules. The medulla showed normal collecting tubules interstitial tissue and blood vessels (Figs. 9, 10, 11, 12 and 13) but there was congestion in interstitial blood vessels with extravasated R.B.Cs in cadmium group (Fig. 10). These results are supported by (Lakshmi *et al.,* 2012) articulated that kidney sections in cadmium treated rats showed vascular and glomerular congestion. Degenerative changes were also observed in proximal tubular epithelium showing cloudy swelling. Also, El- Sokkary *et al.,* (2010) detected that cadmium administration produced sever oxidative damage in liver and kidney. While, treatment of the rats with nigella sativa, garlic or zinc plus cadmium did not cause any effect to stop the harmful effect of cadmium on kidney.

Testis histopathological changes:

The testis structure of the control, Nigella sativa, garlic, cadmium and zinc groups revealed normal architecture. The seminiferous tubules in the above groups were normal in arrangement and composition of spermatogonia, primary and secondary spermatocytes and sperm. Normal interstitial Leydig cells were found. However, in zinc

treated groups the section of testis showed an increase in the number of sperm. Also, there was mild congestion of seminiferous blood vessels in cadmium group.

Treatment of the rats with Nigella sativa plus cadmium decreased the side effect of cadmium on seminiferous blood vessels. Meanwhile, treatment of the rats with garlic or zinc plus cadmium succeeded to prevent the side effect of cadmium on seminiferous blood vessels to returns to normal state. Also treatment with zinc plus cadmium caused mild increase in sperm numbers.

The above results indicate that cadmium caused mild congestion of seminiferous blood vessels. These results are in agreement with the findings of Obianime and Roberts, (2009) indicated that cadmium in the dose ranged from 0 - 40 mg/kg caused a gradual damage but dose and time dependent damage to the histological of the testis. This damage was characterized by destruction of germ cells and somniferous tubules, vascular congestion, focal necrosis of tissue, reduction of spermtocytes, pyknosis, destruction of nucleus, oedema in the seminiferous tubules and interstitial tissue.

Treatments with Nigella sativa, garlic or zinc plus cadmium prevent some or all of toxic effect of cadmium on testis histology.

Sadik (2008) indicated that administration of zinc with cadmium ameliorated cadmium-induced testicular damage. Amara *et al.,* (2008) discovered that zinc administration minimized oxidative damage and reversed the impairment of spermatogenesis and testosterone production induced by cadmium in rat testes. Al-Saaidi *et al.,* (2009) informed that treatment of the rats with alcoholic extract of Nigella sativa showed a significant increase in diameter and wall thickness of the seminiferous tubules, account for spermatogonia, primary and secondary spermatocytes, spermatids and free spermatozoa in the seminiferous tubule lumen.

Liver

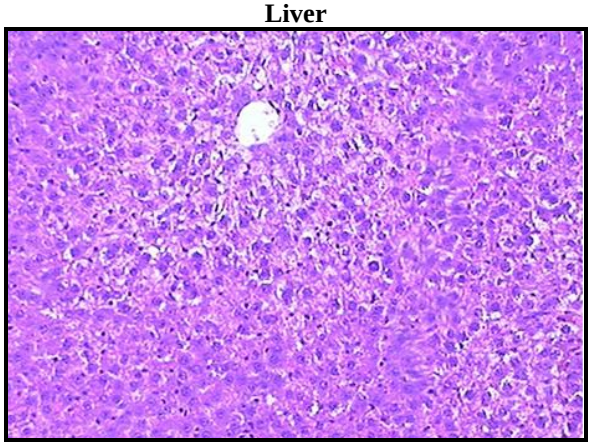

Fig. 1: Shows section in hepatic tissue in liver of the control group revealed preserved normal lobular architecture.
The central vein and portal tracts were normal.
The hepatocytes were normal in arrangement & sinusoid.
The cytoplasm and nuclei were normal. (H & E X100)

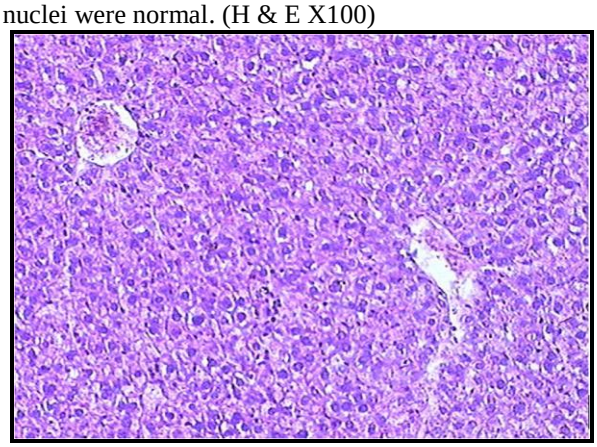

Fig. 2: Shows section in hepatic tissue in liver of the cadmium group revealed preserved normal lobular architecture.
The central vein was congested with mild congestion in hepatic sinusoids.
The hepatocytes were normal in arrangement & sinusoid.
The cytoplasm and nuclei were normal. (H&E X100)

Middle East East j. Appl. Sci.., 4(3): 539-554, 2014

Liver

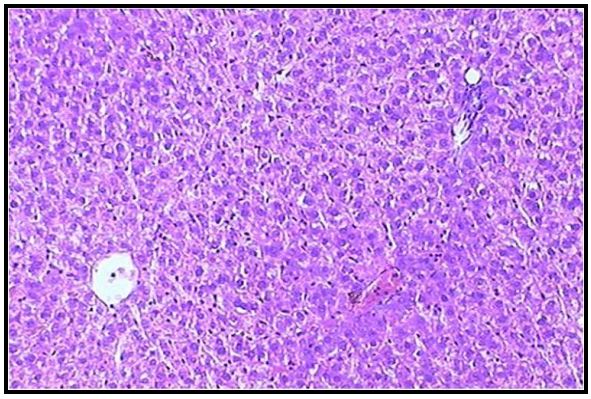

Fig. 3: Shows section in hepatic tissue in liver of Nigella sativa group revealed preserved normal lobular architecture.
The central vein and portal tracts were normal.
The hepatocytes were normal in arrangement & sinusoid.
The cytoplasm and nuclei were normal. (H&E, X100)

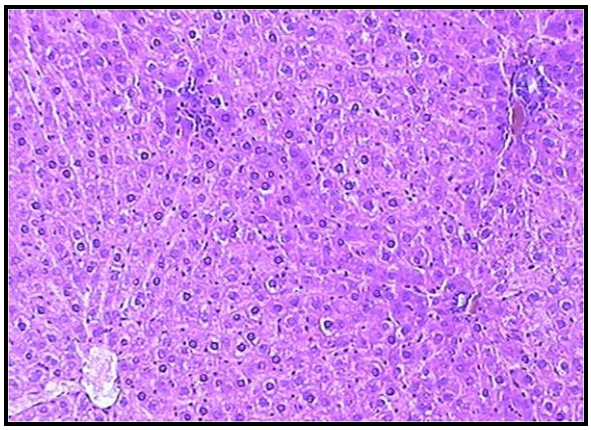

Fig. 4: Shows section in hepatic tissue in liver of garlic group revealed preserved normal lobular architecture.
The central vein and portal tracts were normal.
The hepatocytes were normal in arrangement & sinusoid.
The cytoplasm and nuclei were normal. (H&E X100).

Liver

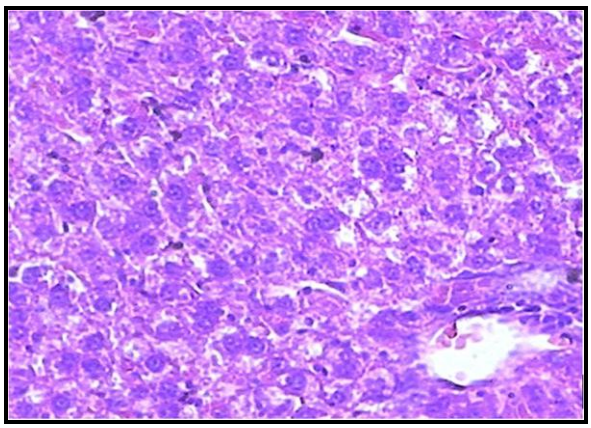

Fig. 5: Shows section in hepatic tissue in liver of zinc group revealed preserved normal lobular architecture.
The central vein and portal tracts were normal.
The hepatocytes were normal in arrangement & sinusoid.
The cytoplasm and nuclei were normal. (H&E X100)

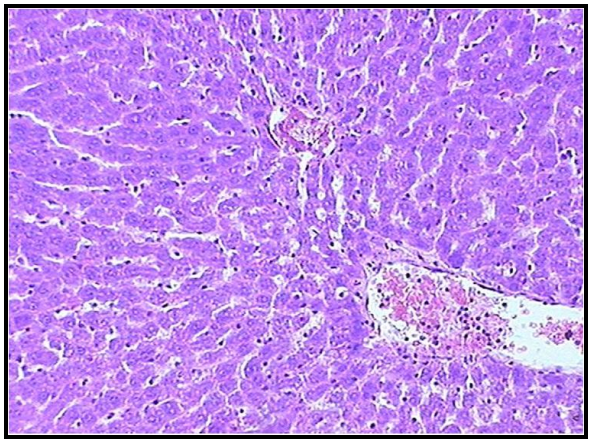

Fig. 6: Shows section in hepatic tissue in liver of cadmium plus nigella sativa treated group revealed preserved normal lobular architecture.
The central vein was congested &normal portal tracts.
The hepatocytes were normal in arrangement & sinusoid.
The cytoplasm and nuclei were normal (H&E X100)

Liver

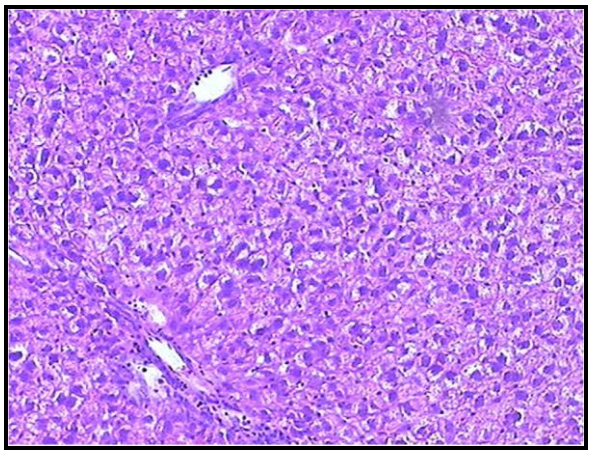

Fig. 7: Shows section in hepatic tissue in liver of cadmium plus garlic treated group revealed preserved normal lobular architecture.
The central vein and portal tracts were normal.
The hepatocytes were normal in arrangement & sinusoid.
The cytoplasm and nuclei were normal. (H&E X100)

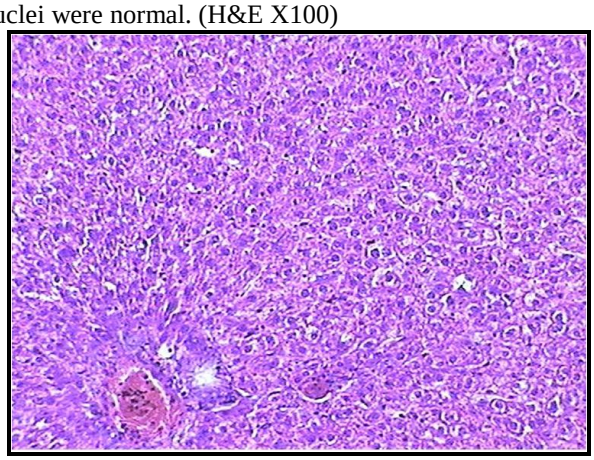

Fig. 8: Shows section in hepatic tissue in liver of cadmium plus zinc treated group revealed preserved normal lobular architecture.
The central vein was congested &normal portal tracts.
The hepatocytes were normal in arrangement & sinusoid.
The cytoplasm and nuclei were normal (H&E X100)

Kidney

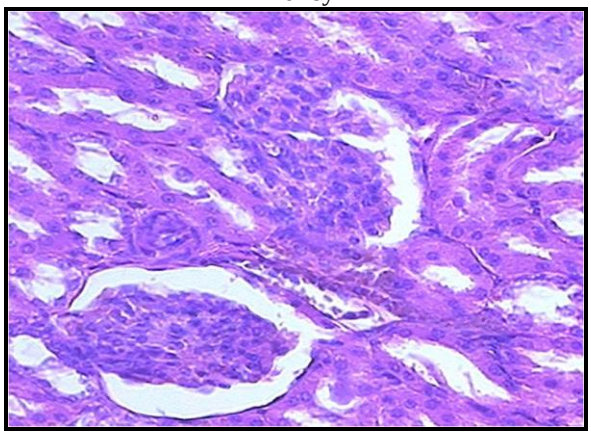

Fig. 9: Shows section in the kidney tissue in the control group revealed preserved normal architecture. The cortex showed normal renal glomeruli and tubules. The medulla showed normal collecting tubules and interstitial tissue & blood vessels. (X 200. H & E)

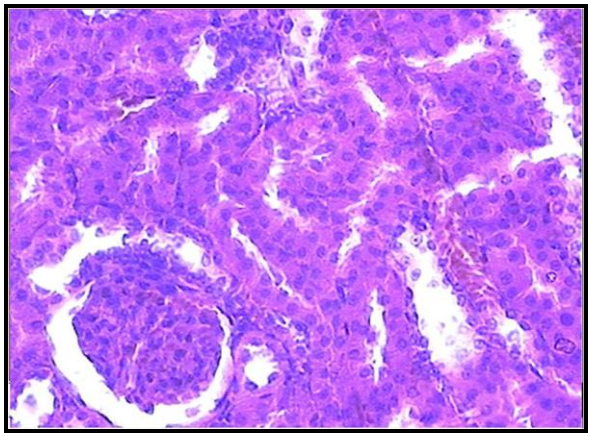

Fig. 10: Shows section in the kidney tissue of the cadmium group revealed preserved normal architecture. The cortex showed normal renal glomeruli and tubules. The medulla showed normal renal tubules and congested interstitial blood vessels with extravasted R.B.Cs. {X 200. H & E}

Kidney

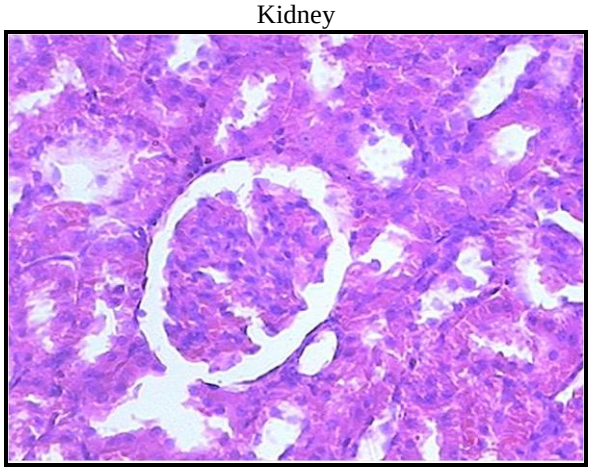

Fig. 11: Shows section in the kidney tissue of nigella sativo group revealed preserved normal architecture. The cortex showed normal renal glomeruli and tubules. The medulla showed normal collecting tubules and interstitial tissue & blood vessels. {X 200. H & E}

Middle East East j. Appl. Sci.., 4(3): 539-554, 2014

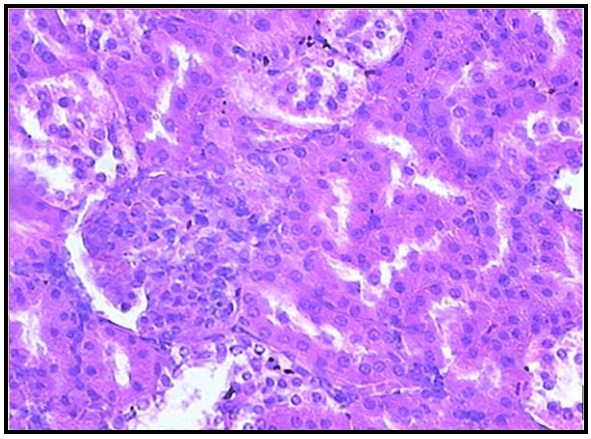

Fig. 12: Shows section in the kidney tissue in garlic group revealed preserved normal architecture.
The cortex showed normal renal glomeruli and tubules.
The medulla showed normal collecting tubules and interstitial tissue & blood vessels. {X 200. H & E}
Kidney

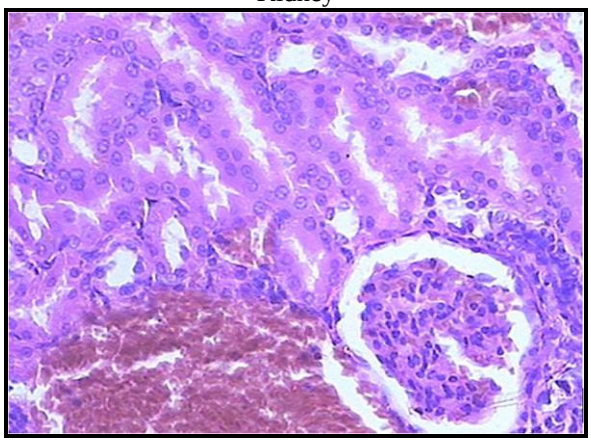

Fig. 13: Shows section in the kidney tissue in zinc group revealed preserved normal architecture.
The cortex showed normal renal glomeruli and tubules.
The medulla showed normal collecting tubules and interstitial tissue & blood vessels. {H & E, X 200}

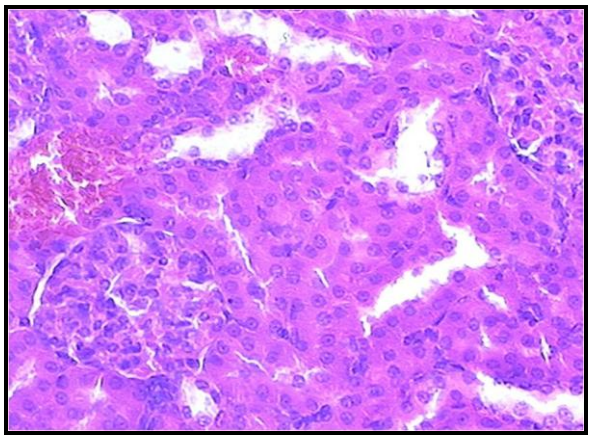

Fig. 14: Shows section in the kidney tissue in cadmium plus nigella sativa treated group revealed preserved normal architecture.
The cortex showed normal renal glomeruli and tubules.
The medulla showed normal renal tubules and congested interstitial blood vessels with extravasted R.B.Cs. {X 200. H & E}

Middle East East j. Appl. Sci.., 4(3): 539-554, 2014

Kidney

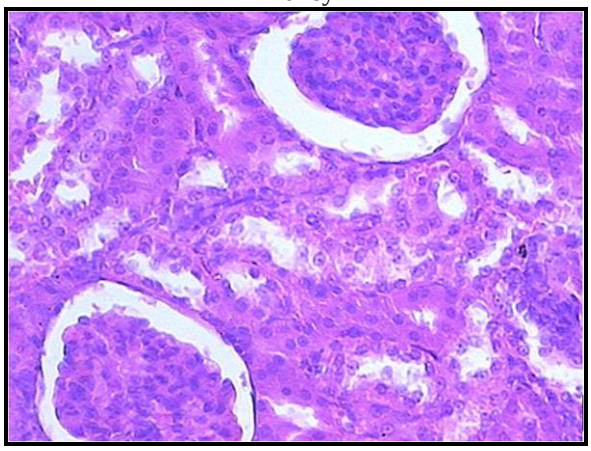

Fig. 15: Shows section in the kidney tissue in cadmium plus garlic treated group revealed preserved normal architecture.
The cortex showed normal renal glomeruli and tubules.
The medulla showed normal renal tubules, mild congested interstitial blood vessels. {H & E, X 200}

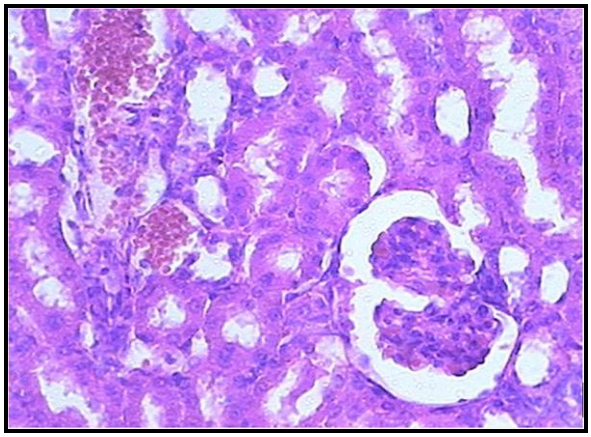

Fig. 16: Shows section in the kidney tissue in cadmium plus zinc treated group revealed preserved normal architecture.
The cortex showed normal renal glomeruli and tubules.
The medulla showed normal renal tubules and congested interstitial blood vessels with extravasted R.B.Cs. {X 200. H & E}

Testis

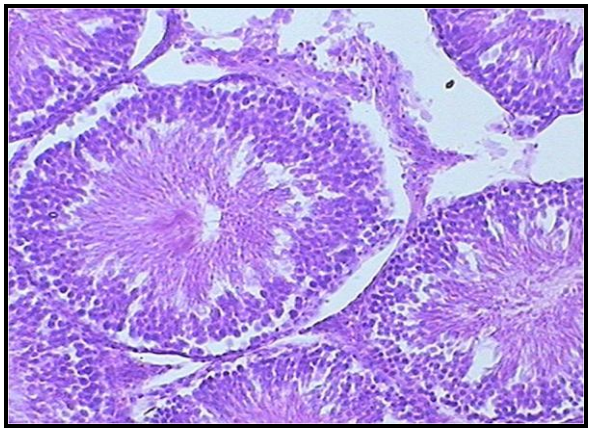

Fig. 17: Shows section in the testicular tissue in the testis of control group showed preserved normal architecture.
The seminiferous tubules were normal in arrangement and composition of spermatogonia, primary, secondary spermatocytes and sperm. Normal interstitial leydig cells were found. (H&E, X100)

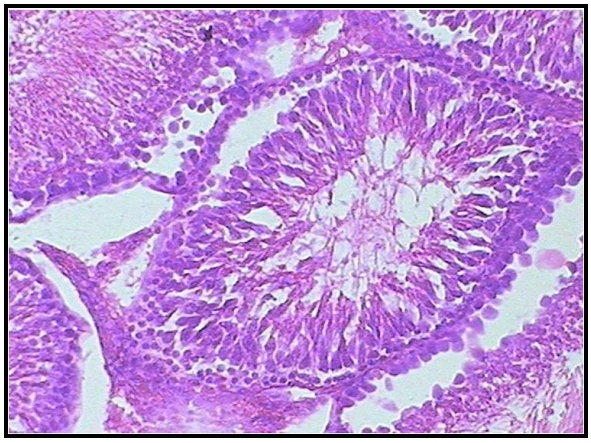

Fig. 18: Shows section in the testicular tissue in the testis of the cadmium group showed preserved normal architecture.
The seminiferous tubules were normal in arrangement and composition of spermatogonia , primary, secondary spermatocytes and sperm. Normal interstitial leydig cells were found. There was mild congestion of seminiferous blood vessels. (H&E, X100)

Testis

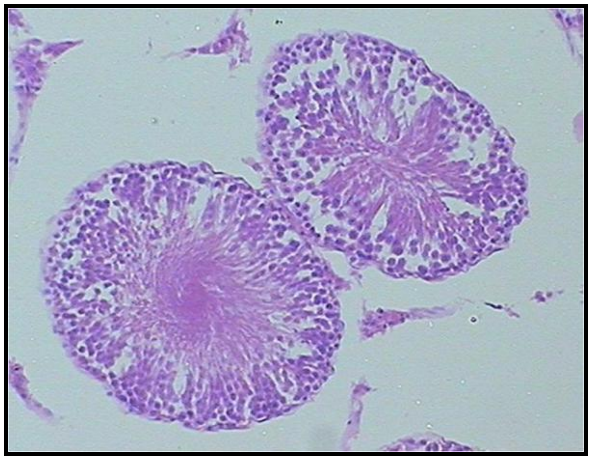

Fig. 19: Shows section in the testicular tissue in the testis of the nigella setiva group showed preserved normal architecture.
The seminiferous tubules were normal in arrangement and composition of spermatogonia , primary, secondary spermatocytes and sperm . Normal interstitial leydig cells were found. (H&E, X100)

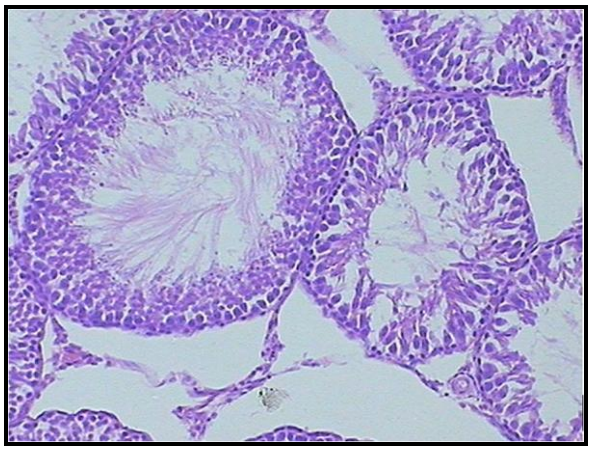

Fig. 20: Shows section in the testicular tissue in the testis of the garlic group showed preserved normal architecture.
The seminiferous tubules were normal in arrangement and composition of spermatogonia , primary, secondary spermatocytes and sperm . Normal interstitial leydig cells were found (H&E , X100)

Middle East East j. Appl. Sci.., 4(3): 539-554, 2014

Testis

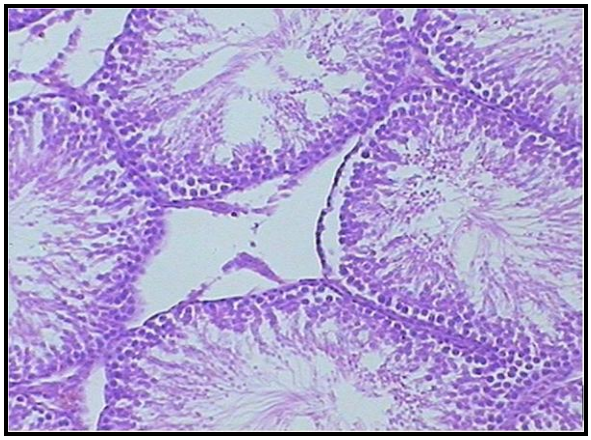

Fig. 21: Shows section in the testicular tissue in the testis of the zinc group showed preserved normal architecture.
The seminiferous tubules were normal in arrangement and composition of spermatogonia , primary, secondary spermatocytes and sperm. Normal interstitial leydig cells were found. There was increase of sperm numbers. (H&E, X100)

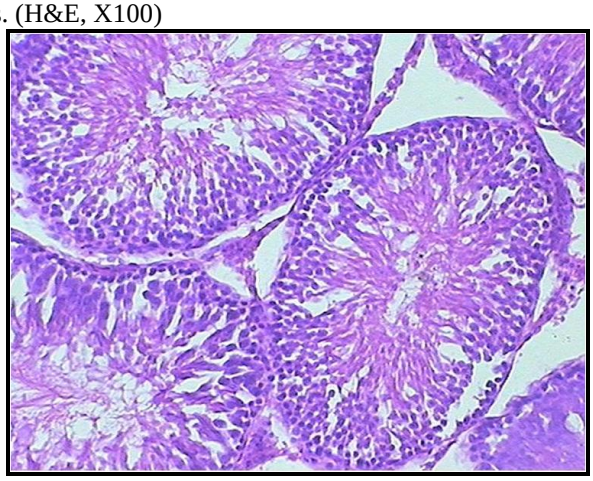

Fig. 22: Shows section in the testicular tissue in the testis of the in cadmium plus nigella sativa treated group showed preserved normal architecture.
The seminiferous tubules were normal in arrangement and composition of spermatogonia , primary, secondary spermatocytes and sperm. Normal interstitial leydig cells were found. There was minimal congestion of interstitial blood vessels. (H&E, X100)

Testis

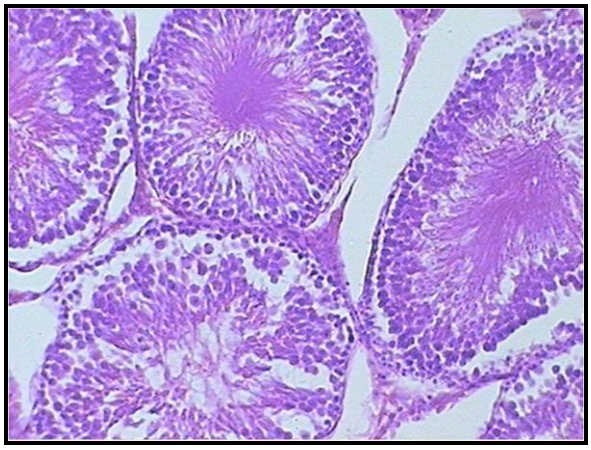

Fig. 23: Shows section in the testicular tissue in the testis of the cadmium plus garlic treated group showed preserved normal architecture.
The seminiferous tubules were normal in arrangement and composition of spermatogonia, primary, secondary spermatocytes and sperm. Normal interstitial leydig cells were found. (H&E., X100)

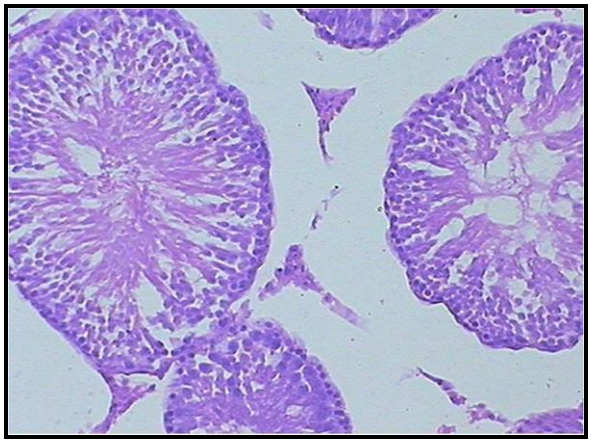

Fig. 24: Shows section in the testicular tissue in the testis of the cadmium plus zinc treated group showed preserved normal architecture.
The seminiferous tubules were normal in arrangement and composition of spermatogonia , primary, secondary spermatocytes and sperm. Normal interstitial leydig cells were found. There was mild increase number of sperm. (H&E, X100)

Blood Plasma Parameters:

Effect of application of Nigella sativo, garlic, cadmium or zinc and their combinations in the rats on Serum total proteins, albumin and globulin at 30 and 60 days of experiment are presented in Table (1, 2, and 3). The results of Serum total proteins and albumin were significantly ($P \leq 0.05$) higher in all groups of experiment except cadmium group was significantly ($P \leq 0.05$) lower in the Serum total proteins, albumin compared to control and other groups. Treatment with Nigella sativo, garlic or zinc alone did not show any significant effect on Serum total protein and albumin. Treatment of rats with Nigella sativa garlic or zinc plus cadmium significantly stopped the reduction in Serum total protein and albumin due to cadmium exposure to reach the normal range in the control group.

Table 1: Shows means ± SE of Serum Total Protein (g/dL) of rats treated orally with cadmium, Nigella sativa, garlic, zinc and their combinations.

Treatments/ Age	Total Protein (g/dL)	
	30 days	60 days
Control	8.4 ± 0.5 A	8.5 ± 0.7 A
Cadmium	6.6 ± 0.4 B	6.3 ± 0.5 B
Nigella Sativa	8.5 ± 0.4 A	8.9 ± 0.7 A
Garlic	8.8 ± 0.7 A	8.5 ± 0.8 A
Zinc	8.3 ± 0.5 A	8.7 ± 0.7 A
Cadmium + Nigella Sativa	8.3 ± 0.3 A	8.1 ± 0.4 A
Cadmium + Garlic	8.9 ± 0.4 A	8.4 ± 0.3 A
Cadmium + Zinc	8.2 ± 0.3 A	8.5 ± 0.2 A

Means in columns with different superscripts are different at ($P \leq 0.05$)

Table 2: Shows means ± SE of Serum Albumin (g/dL) of rats treated orally with cadmium, Nigella sativa, garlic, zinc and their combinations.

Treatments/ Age	Albumin (g/dL)	
	30 days	60 days
Control	6.1 ± 0.4 A	6.4 ± 0.3 A
Cadmium	3.1 ± 0.2 B	3 ± 0.2 B
Nigella Sativa	6.5 ± 0.3 A	6.6 ± 0.5 A
Garlic	6.8 ± 0.6 A	6.5 ± 0.5 A
Zinc	6 ± 0.3 A	6.5 ± 0.4 A
Cadmium + Nigella Sativa	6.1 ± 0.2 A	6 ± 0.3 A
Cadmium + Garlic	6.4 ± 0.3 A	6.1 ± 0.2 A
Cadmium + Zinc	6.2 ± 0.3 A	6.3 ± 0.2 A

Means in columns with different superscripts are different at ($P \leq 0.05$)

The significant reduction in Serum total protein and albumin due to cadmium administration are in agreement with El-bamby (2010) demonstrated that administration of cadmium to the rats significantly decreased total protein and albumin. Meanwhile, treatment with cadmium plus Nigella sativa, garlic or zinc succeeded to increase Serum total protein and albumin to reach the normal range in the control group.

The reduction in Serum total protein and albumin levels are indicating that cadmium caused poor liver function that impaired synthesis of albumin in the liver which clearly appeared in liver histopathological

examination. Meanwhile, treatment with Nigella sativa, garlic or zinc can repair or remedy the disorder of liver that caused by cadmium. Abd and Baghdadi (2009) disclosed that garlic oil significantly increased serum total protein in carbon tetra chloride (CCI4) when treated with rabbits. Ademiluyi *et al.,* (2013) pronounced that control rats administered gentamycin and fed basal diet exhibited significantly reduced plasma albumin level which was restored to near normal in diets containing either 2% or 4% garlic inclusion. Al - Saaidi *et al,* (2009) observed that treatment of rats with alcoholic extract of Nigella sativa significantly increased serum total protein compared with control animals.

Results of globulin are given in Table (3). The results showed that treated rats with cadmium for a period of 30 -60 days was significantly ($P \leq 0.05$) increased the Serum globulin compared to other groups. Whereas, treatment with Nigella sativa, garlic, zinc alone or integrated with cadmium did not show any significant effect on Serum globulin as compared with the control group and significantly stopped the increase of Serum globulin occurred when cadmium was added alone so its level did not differ significantly than the control one. The reduction in the Serum total protein, albumin and globulin in the cadmium group may be attributed to the damaged occurred in the liver as shown in the results of histopathological examination. The increased Serum concentration of total protein, albumin and decreased of globulin in all groups compared to cadmium group may be indicative of enhanced immune system as the Serum concentration of albumin protein antioxidant status are regarded as the direct reference to the body immune function (Zhang *et al.,* 2013).

Table 3: Shows means ± SE of Serum Globulin (g/dL) of rats treated orally with cadmium, Nigella sativa, garlic, zinc and their combinations.

Treatments/ Age	Globulin (g/dL)	
	30 days	60 days
Control	2.3 ± 0.1 B	2.1 ± 0.4 B
Cadmium	3.5 ± 0.2 A	3.3 ± 0.2 A
Nigella Sativa	2 ± 0.1 B	2.3 ± 0.2 B
Garlic	2.5 ± 0.1 B	2 ± 0.3 B
Zinc	2.3 ± 0.2 B	2.2 ± 0.3 B
Cadmium + Nigella Sativa	2.2 ± 0.1 B	2.1 ± 0.1 B
Cadmium + Garlic	2.5 ± 0.1 B	2.3 ± 0.1 B
Cadmium + Zinc	2 ± 0.1 B	2.2 ± 0.3 B

Means in columns with different superscripts are different at (P≤0.05)

The results of administration of Nigella sativo, garlic, cadmium or zinc and their combinations in the rats on Serum AST and ALT activities are shown in Table (4 and 5). The achieved results at 30 and 60 days showed that all values of both AST and ALT were in normal range for all experimental groups except cadmium group was recorded significantly ($P \leq 0.05$) higher AST and ALT values compared to all other groups. This means that cadmium treatment significantly ($P \leq 0.05$) increased Serum ALT and AST compared to all other groups. These results may be referred to the damage happened in the liver due to treatment rats with cadmium as observed in histopathological results of liver. Also, the increment observed in AST and ALT activities by cadmium administration in this study can be indicative of bad or inferior function of liver and appear pathological metabolism of the liver which may reflect a bad health of rats subjected to this group. Lakshmi (2011) established that the functional markers of liver such as total protein and albumin were significantly ($P \leq 0.05$) decreased while the ALT levels were significantly increased following cadmium administration.

Table 4: Shows means ± SE of Serum AST (U/L) of rats treated orally with cadmium, Nigella sativa, garlic, zinc and their combinations.

Treatments/ Age	AST(U/L)	
	30 days	60 days
Control	165.9 ± 3.3 B	166.7 ± 3.7 B
Cadmium	187.8 ± 4.1 A	190.3 ± 4.5 A
Nigella Sativa	168.1 ± 3.9 B	169.7 ± 4.2 B
Garlic	167 ± 3.1 B	167.3 ± 2.2 B
Zinc	166.1 ± 3.7 B	167.3 ± 3.8 B
Cadmium + Nigella Sativa	168.5 ± 3.5 B	169.3 ± 3.1 B
Cadmium + Garlic	167.8 ± 3.2 B	168.1 ± 3.7 B
Cadmium + Zinc	167 ± 4.1 B	167.3 ± 4.3 B

Means in columns with different superscripts are different at (P≤0.05)

Tables (4 and 5) also showed that Nigella sativa, garlic or zinc alone did not show any significant effect on Serum ALT and AST as compared with the control group while treatment of rats with Nigella sativa, garlic or zinc plus cadmium significantly stopped the increase in Serum ALT and AST accompanied exposure of rats to cadmium alone to reach the normal range in the control group. These results indicated that Nigella sativa, garlic or zinc have a hepatoprotective effect against cadmium hepatotoxicity. Abd and Al- Baghdadi (2009) revealed that the use of garlic oil produced significant reduction in the level of ALT, AST and ALP and reverted the tissue of the liver back to normal situation. Thus, use of garlic oil possesses hepatoprotective activity by restoring the normal

hepatic functions and potentiating the bio- defense system of the liver against hepatotoxicity produced by carbon tetra chloride (CCl_4) administration. Dollah *et al.,* (2013) find out that there was no significant decrease in serum ALT of rats following supplementation with Nigella sativa. This small reduction of ALT was dose dependent. It means that consumption of high dose of Nigella sativa resulted in higher reduction of Serum ALT level. They also revealed that Nigella sativa administration decreased Serum AST in all groups in comparison with control group, while the Serum AST level was decreased in high dose Nigella sativa administrated group more than other treatment group. Kang *et al.,* (2008) exposed that zinc supplementation enhances liver regeneration at least in part by HNF-4 alpha (hepatocyte nuclear facror -4 alpha) through the up-regulation of cell proliferation- related proteins, suggesting that dietary zinc supplementation may have beneficial effects in alcoholic liver disease.

Table 5: Shows means ± SE of Serum ALT (U/L) of rats treated orally with cadmium, Nigella sativa, garlic, zinc and their combinations.

Treatments/ Age	ALT(U/L)	
	30 days	60 days
Control	43.8 ± 2.2 B	45.1 ± 2.7 B
Cadmium	66.5 ± 3.5 A	70.3 ± 3.7 A
Nigella Sativa	43.1 ± 3.5 B	44.7 ± 2.1 B
Garlic	45.1 ± 1.8 B	46.3 ± 1.7 B
Zinc	45.9 ± 2.1 B	45.7 ± 2.5 B
Cadmium + Nigella Sativa	44.3 ± 2.7 B	45 ± 2.9 B
Cadmium + Garlic	45.9 ± 2.7 B	46.8 ± 2.5 B
Cadmium + Zinc	44.7 ± 2.6 B	45.5 ± 2.3 B

Means in columns with different superscripts are different at (P≤0.05)

Table (6) showed that treatment of rats with cadmium for 30 or 60 days significantly ($P \leq 0.05$) increased Serum urea as compared with the control group. Treatment of rats with Nigella sativa, garlic or zinc alone did not show any significant effect on Serum urea as compared with the control group. Treatment with cadmium plus Nigella sativa, garlic or zinc did not pause the significant increase in Serum urea due to cadmium administration alone.

Table 6: Shows means ± SE of Serum Urea (mg/dL) of rats treated orally with cadmium, Nigella sativa, garlic, zing and their combinations.

Treatments/ Age	Urea (mg/dL)	
	30 days	60 days
Control	50.1 ± 3.7 B	52.5 ± 3.2 B
Cadmium	65.6 ± 3.8 A	71.2 ± 3.5 A
Nigella Sativa	51.3 ± 3.6 B	55.9 ± 2.3 B
Garlic	52.5 ± 2.8 B	55.1 ± 2.7 B
Zinc	51.5 ± 3.1 B	50.9 ± 2.9 B
Cadmium + Nigella Sativa	66.5 ± 3.3 A	72.2 ± 2.9 A
Cadmium + Garlic	63.1 ± 3.1 A	69.8 ± 2.8 A
Cadmium + Zinc	51.3 ± 2.7 A	72.7 ± 2.5 A

Means in columns with different superscripts are different at (P≤0.05)

Based on the obtained results, it can be conclude that Nigella sativa, garlic or zinc may offer a measure of protection against the cadmium toxicity by maintaining the disturbed levels of the Serum total protein, albumin, ALT and AST either up or down, near the normal levels and by maintaining the liver and testes histological form as in the control group. Meanwhile the protective effect of Nigella sativa, garlic and zinc against the toxic effect of cadmium on the kidney structure and functions need more studies to draw final conclusions.

References

Abd El hamid, A.A., 2012. Effect of selenium on some physiological parameters in rats treated with cadmium. Egypt . J. med Sci, 33(1): 601-613.

Abd, A.J. and R.J.T. Al-Baghdadi, 2009. Effects of garlic oil in correction of hepatotoxicity induced by CCl_4 in rabbits Al- Anbar J. Vet. Sci., 2(2): 7-13.

Ademiluyi, A.O., G. Ohoh, T.R. owoloye and O.J. Agbebi, 2013. Modulatory effects of dietary inclusion of garlic (Allium sativum) on gentamycin - induced hepatotoxicity and oxidative stress in rats. Asian Pac. J. trop. Biomed., 3(6): 470-475.

Al-Hashem, F., D. Mohammad, N. Bashir, A. Mohammad, E. Riyadh, K. Mohammad and M. Al-Khateeb, 2009. Camel's milk protects against cadmium chloride inderced toxicity in white albino rats. American Journal of pharmacology and toxicology, 4(3): 107-117.

Al-Saaidi, J.A.A., A.L.D. Al-Khuzai and N.F.H. Al-Zobaydi, 2009. Effect of alcolic extract of nigella sativa on ertility in male rats. Iraqi Journal of Veterinary sciences, 23: 123-128.

Ali, B.H. and G. Blunden, 2003. Pharmacological and toxicological properties of nigella sativa. Phytother res., 17: 299-305.

Amara, S., H. Abdelmelek, C. Garrel, P. Giraud, T. Douki, J.L. Ravanat, A. Favier, M. Sakly and K.B. Rhouma, 2008. Preventive effect of zinc against cadmium induced oxidative stress in the rat testis. Journal of Reproduction and Development, 54(2): 129-134.

Badr, M.I., H.H. Khalifa, A.A. Abd El-Hamid, M.H. Khalil and E.L. Koatb, 2012. Protective effect of some medicinal plants on blood parameters, kidney and liver function and histopathogical features of kidney in rats. Egyptian J. Anim. Prod., 49(2): 233-240.

Dollah, M.A., S. Parhizkar, L.A. latiff and M.H.B. Hassan, 2013. Toxicity effectr of nigella sativa on the liver function of rats. Aolvanced pharmaceutical bulletin, 3(1): 97-102.

Dumas, B.T. and H.G. Biggs, 1972. In standard methods of clinical chemistry vol 7 academic press. New York P. 175.

Duncan, D.B., 1955. Multiple range and multiple F test. Biometrics, 11: 1-42.

El-Heni, J., I. Messoudi, F. Hammouda and A. Kerkeni, 2009. Protective effects of selenium (se) and zinc (zn) on cadmium (Cd) toxicity in the liver of the rat: Effects on the oxidative stress. Ecotoxicology and Environmental safety, 72: 1559-1564.

El-Sokkary, G.H., A.A. Nafady and E.M. Shobash, 2010. Melatonin administration ameliorates cadmium induced oxidative stress and morphological changes in the liver - of rat ecotoxicology and environmental safety, 73(3): 456.

El-Bamby, 2010. Toxicological effects of some environmental pollutants on rats. Ph D thesis, fac. Of agric. Al - Azhar univ. Cairo, Egypt.

Friberg, L., C.G. Elinder and T. Kjellstrom, 1992. Environmental Health Criteria (EHC) 134: Cadmium. World Health Organization. Geneva.

Henry, R.J., 1964. Clinical Chemistry, Harper and row publishers, New York, pp: 181.

Henry, J.B., 1974. Clincal diagnosis and management by laboratory method W.B saunders co., Philadelphia 361.

Hosseinzadeh, H. and R. Montahaei, 2007. Protective effect of nigella sativa L. extracts and thymoquinone, its active constituent, on renal ischemia - reperfusion - induced oxidative damage in rats. Pharmacology online 1: 176-189.

Kang, X.Q., Z.Y. Song, C.J. Mcclain, Y.J. Kang and Z.X. Zhou, 2008. Zinc supplementation Enhances hepatic regeneration by preserving hepatocyte nuclear factor - 4 alpha in mice subjected to long - term ethanol administration. American journal of pathology, 172(4): 916-925.

Lakshmi, G.D., P.R. Kumar, K. Bharavi, P. Annapurna, B. Rajendar, P.T. Patel, C.S.V.S. Kumar and G.S. Rao, 2012. Protective effect of tribulus terrestris linn on liver and kidney in cadmium intoxicated rats. Indian journal of experimental. Biology, 50: 141-146.

Masso, E.L., L. Corridor and M.T. Antonion, 2007. Oxidative damage in liver after perinatal intoxication with lead and / or cadmium. Journal of trace elements in medicine and biology, 21(3): 210-216.

Obianime, A.W. and I.I. Roberts, 2009. Antioxidants cadmium - induced toxicity, serum biochemical and the histological abnormalities of the kidney and testes of the male wistar rats. Nigerian journal of physiological sciences, 24(2): 177-185.

Obioha, U.E., S.M. Suru, K.F. Ola- Mudathir and T.Y. Faremi, 2009. Hepatoprotective potentials of onion and garlic extracts on cadmium. Induced oxidative damage in rats. Bilogyioal trave element research, 129(3): 143-156.

Pearse, A.G.E., 1968. Histochemistry: Theoretical and Applied, 3rd edition. Churchill living stone. New York. USA., pp: 613-658.

Rajendar, B., K. Bharavi, G.S. Rao, P.V.S. Kishore, P.R. Kumar, C.S.V.S. Kumar and D.S. Kumar, 2011. Protective effect of x- tocopheral on biochemical and histological alterations induced by cadmium in rats testes. Indian J. physiol. Pharacol., 55(3): 213-220.

Reitman, S. and S. Frankel, 1957. A colorimetric method for the determination of serum glutamic oxaloacetic acid and glutamic pyruvic transaminses. Am. J. Clin. Pathol., 28: 56 –63.

Sadik , N.A.H., 2008. Effect of dially 1 sulfide zinc on cadmium - induced oxidative damage and trace elements level in the testes of mal rats. Journal of food biochemistry, 32(5): 672-691.

SAS., 1998. Stistical analysis system institute, SAS user's guide statistics, 5th edition. SAS institute inc., cary, NC.

Suru, S.M., 2008. Onion and garlic extracts lesson cadmium - induced nephrotoxicity in rats biometals, 21: 623-633.

Tobacco A., F. Meiattini, E. Moda and P. Tarli, 1979. Simlified enzymatic/colorimetric serum urea nitrogen determination. Clin. Chem., 25: 336 – 337.

Tsalev, D.L. and Z.K. Zprianov, 1993. Atomic Absorption spectrometry in occupational and environmental health practice, (CRC press, Boca Raton: FL. USA): 105.

Vazquez-prieto, M.A., C.R. Lanzi, C. Lembo, C.R. Galmarini and R.M. Miatello, 2011. Garlic and onion attenuates vascular inflammation and oxidative stress in fructosefed fats. J. Nutr. Metab. DOI: 10: 1155.

Zhang, N., J. Li, Y. Hu, G. Cheng, X. Zhu, F. Liu, Y. Zhang, Z. Liu and J. Xu, 2010. Effects of *Astragalus* polysaccharide on the immune response to foot-and-mouth disease vaccine in mice. Carbohydr. Polym., 82: 680-686.